



PATIENT

Sonny Waishek

SPECIES

Canine

BREED

Chihuahua

SEX

Male Neutered

AGE

10 years

WEIGHT

9lbs

INTERPRETED BY

Maggie Machen
Lamy, DVM
DACVIM (Cardiology)

IMAGING

PERFORMED BY

Pamela Harrigan,
RDMS

HOSPITAL NAME

Parkway Veterinary
Hospital

REFERRING VET

Dr. Lysz

INVOICE

26899

DATE

10/14/22

PRESENTING CLINICAL SIGNS

History: Recheck echo. History chronic valvular disease - Stage B2, with modest progression at the time of prior echo. Currently, occasional cough. Good appetite - doing well overall. BP: 140mmHg x3. Current meds: Pimobendan 2.5 mg/ml oral suspension. 0.5ml PO BID; Simparica trio monthly.

-Pertinent previous echo findings (5/4/22 Rebecca Malakoff, DVM, DACVIM - Cardiology): LA 2.55 cm; LA: Ao 1.89; LV 2.64 cm, moderate LAE, mild LVE, moderate - severe MR, mild TR (3.08m/s; 38 mmHg); mild pulmonary hypertension.

ECHOCARDIOGRAM FINDINGS

2D, m-mode, color flow and Doppler imaging is available.

Left ventricle: The LV diameter is mildly increased with hyperdynamic function. LV wall thicknesses are normal.

Left atrium: The left atrium is moderately dilated.

Mitral valve: The mitral valve is markedly thickened with significant prolapse into the left atrial lumen. Moderate to severe eccentric mitral regurgitation with a normal velocity.

Aortic valve/Aorta: The aortic valve is normal in morphology and mobility. Normal aortic outflow velocity; laminar flow. No aortic insufficiency.

Right ventricle: Normal right ventricular diameter and morphology indicating no overt evidence of pulmonary arterial hypertension.

Right atrium: Normal RA dimension.

Tricuspid valve: The tricuspid valve appears mildly thickened with mild tricuspid regurgitation. Normal velocity.

Pulmonic valve/Pulmonary artery: The pulmonic valve is normal in morphology and mobility. No pulmonic insufficiency. Normal RVOT velocity; laminar flow.

Pericardium/other: No pericardial or pleural effusion noted. No obvious cardiac masses.

Heart rhythm: ECG reveals a sinus rhythm with an average HR of 190bpm.

2-Dimensional Measurements

Ao diam (cm)	1.1
LA diam (cm)	2.5
LA:Ao (Swe)	2.2
IVS thickness (cm)	0.5
LVID diastole (cm)	2.6
PW thickness (cm)	0.5
LVID systole (cm)	1.2
FS (%)	55

Doppler Measurements

PV Vmax (m/s)	0.8
AoV Vmax (m/s)	1.3
MR Vmax (m/s)	5.7
TR Vmax (m/s)	2.7
TR PG (mmHg)	30

INTERPRETATION OF THE FINDINGS

Chronic degenerative valve disease persists with moderate to severe mitral and mild tricuspid regurgitation. Compared to what is available from the prior study, findings appear similar. Moderate left atrial enlargement indicates there is relatively low risk for imminent complication, however risk for progression to spontaneous congestive heart failure in the future is elevated. No additional issues are identified.

Given these findings, continue Pimobendan is recommended as below. Assessment of progression in the future will help predict long term outcome, however prognosis is guarded at this stage (B2).



PATIENT

Sonny Waishek

SPECIES

Canine

BREED

Chihuahua

SEX

Male Neutered

AGE

10 years

WEIGHT

9lbs

INTERPRETED BY

Maggie Machen
 Lamy, DVM
 DACVIM (Cardiology)

IMAGING PERFORMED BY

Pamela Harrigan,
 RDCS

HOSPITAL NAME

Parkway Veterinary
 Hospital

REFERRING VET

Dr. Lysz

INVOICE

26899

DATE

10/14/22

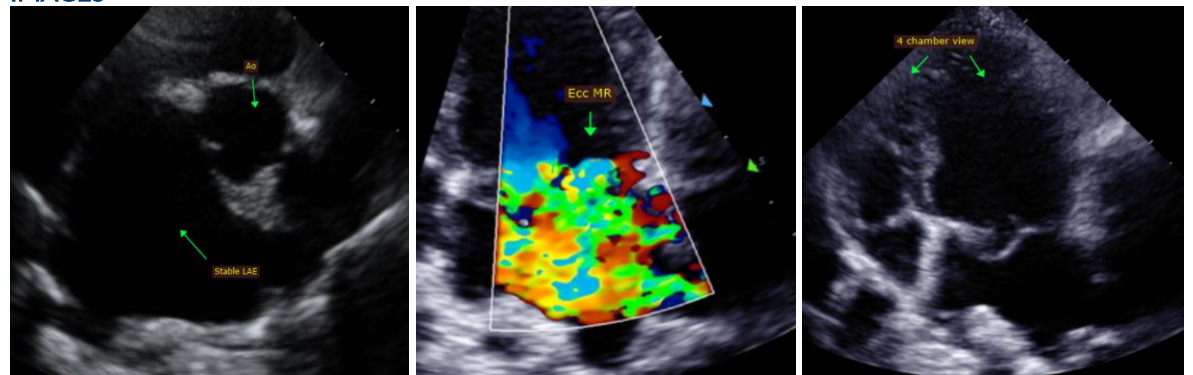
RECOMMENDATIONS

- Continue Pimobendan 0.3mg/kg PO q12h.
- Omega fatty acid supplementation and mild salt restriction may be of some long-term benefit.
- Anesthetic risk is considered mild if needed. Cardiac protective drug choices (opioid/benzodiazepine premedication, propofol or alfaxalone induction, isoflurane gas) are recommended. Pre-oxygenate for 5-10 minutes prior to induction. Monitor for arrhythmias, hypotension, and hypoxia both intra and post-operatively and intervene as necessary. Mild IV fluid restriction is recommended to avoid fluid overload. Avoid heart rate stimulating drugs such as atropine unless clinically indicated.
- Monitor for development of a cough, labored breathing, exercise intolerance or collapse episodes.

PLAN

- Recommend conservative monitoring with a recheck echocardiogram in 6 months, sooner if any development of clinical signs.

IMAGES



The information and recommendations provided are based on the images presented by the referring veterinarian. No evaluation can be communicated regarding pathology that was not visible in the image/video clips provided.

Thank you for this referral. This report was generated using transcription software, and minor dictation errors may be present. If the clinical or image interpretation does not parallel your findings or if I can be of any further assistance, please contact me.

Maggie Machen Lamy, DVM
 Diplomat of the American College of Veterinary Internal Medicine (Cardiology)
 info@sonopath.com